

Table of Contents

भुजा (arm)	3
भुजा (arm) (fascial Compartments of arm)	3
anterior/flexor compartment	3
posterior/extensor compartment	3


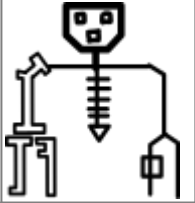
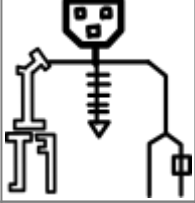

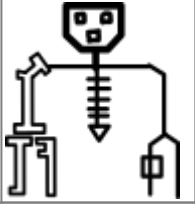

भुजा (arm)

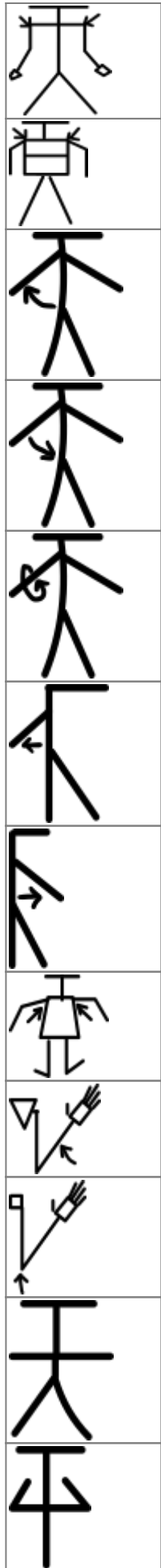
प्रवर्णी भुजा संविभाग (fascial Compartments of arm)

anterior/flexor compartment

Muscle		Origin	Insertion	Artery	Nerve	Action	Antagonist
coracobrachialis	तुंडप्रगंडिका	coracoid process of scapula	medial surface of humerus	brachial artery	musculocutaneous nerve	flexes and adducts shoulder	
biceps brachii	प्रगंडद्विशिरस्का	short head: coracoid process of scapula long head: supraglenoid tubercle	radial tuberosity, bicipital aponeurosis		musculocutaneous nerve (lateral cord: C5, C6, C7)	flexes elbow, supinates forearm	triceps brachii
brachialis	प्रगंडिका	anterior surface of humerus (mainly distal half)	coronoid process of ulna, tuberosity of ulna	radial recurrent artery	musculocutaneous nerve	flexes elbow	

posterior/extensor compartment

triceps brachii
anconeus









From:
<https://mantrakshar.co.in/> - **Kshtrgyn**

Permanent link:
<https://mantrakshar.co.in/doku.php/hi/arms?rev=1666548070>

Last update: **2022/10/23 18:01**

