

# Table of Contents

भुजा (arm) .....	3
<b>भुजा (arm) ( fascial Compartments of arm )</b> .....	3
anterior/flexor compartment .....	3
posterior/extensor compartment .....	3



# भुजा (arm)

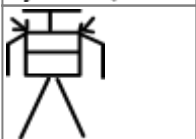
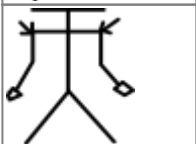
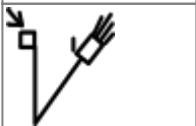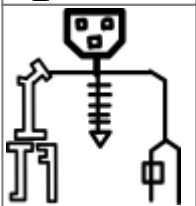
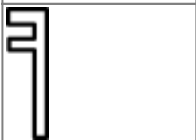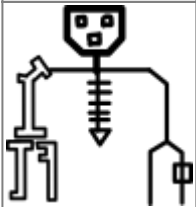
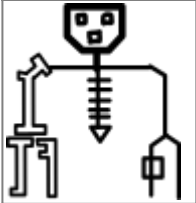
## प्रवरणी भुजा संविभाग ( fascial Compartments of arm )

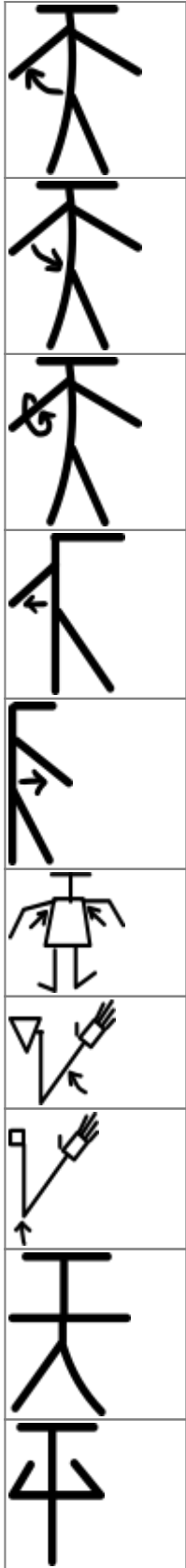
### anterior/flexor compartment

biceps brachii		
brachialis		
coracobrachialis		

### posterior/extensor compartment

triceps brachii		
anconeus		





From:  
<https://mantrakshar.co.in/> - Kshtrgyn

Permanent link:  
<https://mantrakshar.co.in/doku.php/hi/arms?rev=1666547721>

Last update: **2022/10/23 17:55**



