

Table of Contents

FRONT OF NECK	3
ANTERIOR TRIANGLE OF NECK	4

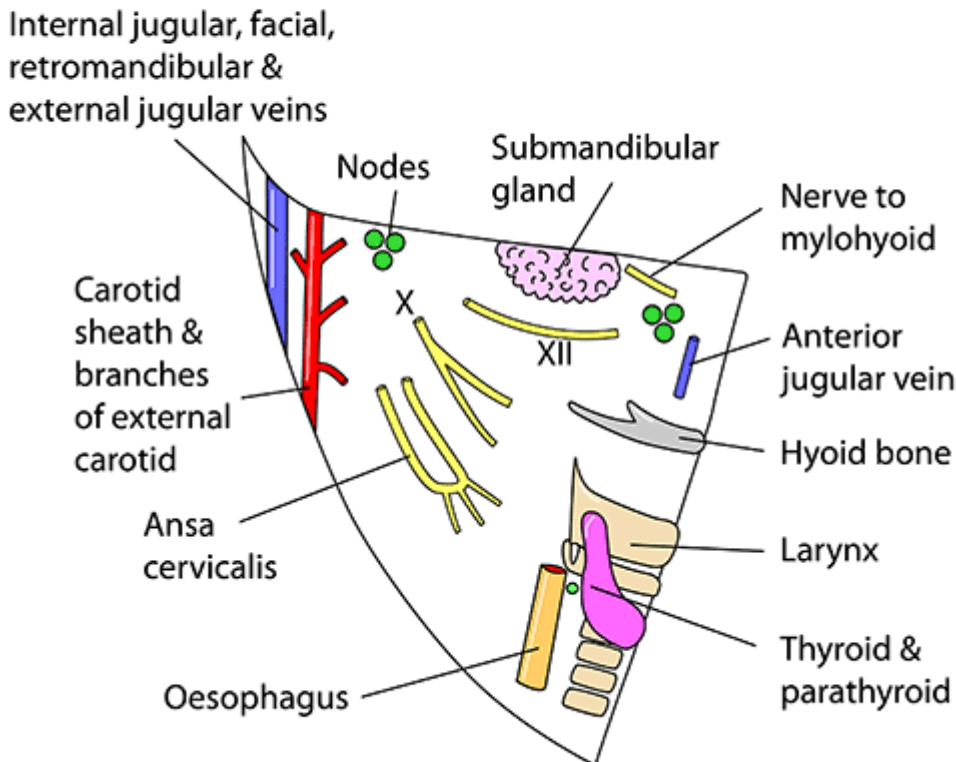
FRONT OF NECK

- BORDERS:
 - - Superior - inferior border of mandible
 - - Medial - midline of neck
 - - Lateral - anterior border of sternocleidomastoid [muscle](#)
- CONTENTS
 - Muscles:
 - thyrohyoid, sternothyroid, sternohyoid muscles
 - Organs:
 - thyroid [gland](#), parathyroid glands, larynx, trachea, esophagus, submandibular [gland](#), caudal part of the parotid [gland](#)
 - Arteries:
 - superior and inferior thyroid, common carotid, external carotid, internal carotid artery (and sinus), facial, submental, lingual arteries
 - Veins:
 - anterior jugular veins, internal jugular, common facial, lingual, superior thyroid, middle thyroid veins, facial vein, submental vein, lingual veins
 - Nerves:
 - vagus [nerve](#) (CN X), hypoglossal [nerve](#) (CN XII), part of sympathetic [trunk](#), mylohyoid [nerve](#)
- Subdivisions:
 - - Muscular (omotracheal) triangle
 - Borders
 - Superior - hyoid bone
 - Lateral - superior belly of omohyoid and anterior border of sternocleidomastoid
 - Medial - midline of neck
 - Contents
 - Muscles: thyrohyoid, sternothyroid, sternohyoid
 - Vessels: superior and inferior thyroid arteries, anterior jugular veins
 - Viscera: thyroid [gland](#), parathyroid glands, larynx, trachea, esophagus
 - - Carotid triangle
 - Borders
 - Anterior - superior belly of omohyoid [muscle](#)
 - Superior - stylohyoid and posterior belly of digastric muscles
 - Posterior - anterior border of sternocleidomastoid [muscle](#)
 - Contents
 - Arteries: common carotid, external carotid (and branches except maxillary, superficial temporal and posterior auricular), internal carotid artery (and sinus)
 - Veins: internal jugular, common facial, lingual, superior thyroid, middle thyroid veins
 - Nerves: vagus [nerve](#) (CN X), hypoglossal [nerve](#) (CN XII), part of sympathetic [trunk](#)
 - - Submandibular triangle
 - Borders
 - Superior - inferior border of mandible
 - Lateral - anterior belly of digastric [muscle](#)

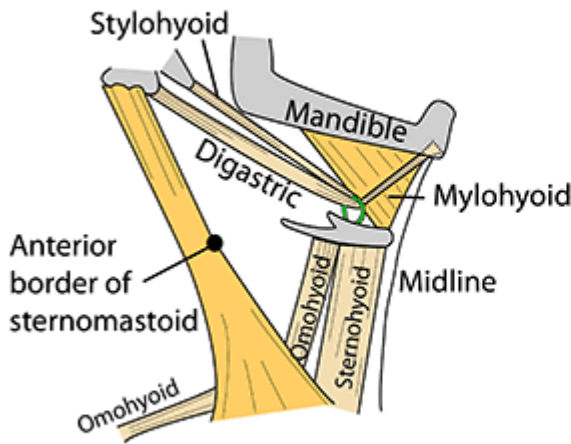
- Medial - posterior belly of digastric muscle
- Contents
 - Viscera: submandibular gland and lymph nodes (anteriorly), caudal part of the parotid gland (posteriorly)
 - Vessels: facial artery and vein, submental artery and vein, lingual arteries and veins
 - Nerves: mylohyoid, hypoglossal (CN XII)
- - Submental triangle
 - Borders
 - Inferior - hyoid bone
 - Lateral - anterior belly of digastric muscle
 - Medial - midline of neck
 - Contents
 - Anterior jugular vein, submental lymph nodes

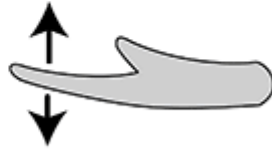
ANTERIOR TRIANGLE OF NECK

RIGHT ANTERIOR TRIANGLE OF NECK DIAGRAM OF CONTENTS



ANTERIOR TRIANGLE OF NECK SUPRAHYOID AND STRAP MUSCLES

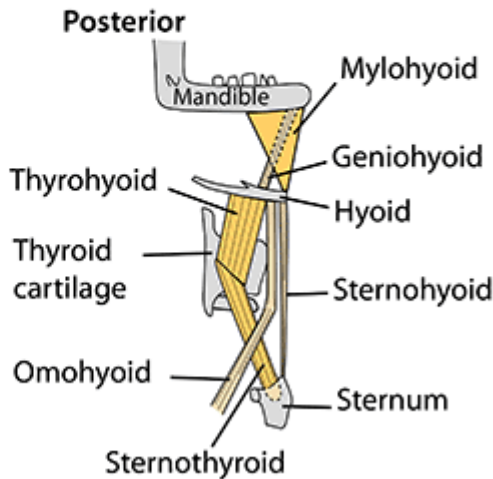
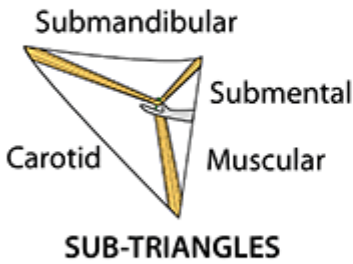


- Digastric — Superficial
 - Stylohyoid — Superficial
 - Mylohyoid — Intermediate
 - Geniohyoid — Deep
- 
- Sternohyoid — Superficial
 - Omohyoid — Superficial
 - Sternothyroid — Deep
 - Thyrohyoid — Deep

Sternomastoid: Each acting alone gives flexion & lateral rotation but acting together - protrusion of head
N: Spinal root of accessory (C1-5)

MUSCLES

Lie between pretracheal & investing fasciae. Supplied by anterior rami of C1-3, ansa cervicalis, facial nerve & nerve to mylohyoid (Vc)



From:

<https://mantrakshar.co.in/> - Kshtrgyn

Permanent link:

<https://mantrakshar.co.in/doku.php/en/front-of-neck?rev=1686915603>

Last update: **2023/06/16 11:40**

